CLINICAL PROCEEDINGS®

NON PROFIT
US POSTAGE
PAID
PERMIT 827
WASHINGTON, DC

ASSOCIATION OF REPRODUCTIVE HEALTH PROFESSIONALS
2401 Pennsylvania Avenue, NW, Suite 350
Washington, DC 20037-1730 USA

Endorsed by:

- AMERICAN CANCER SOCIETY
- AMERICAN COLLEGE HEALTH ASSOCIATION
- AMERICAN MEDICAL WOMEN'S ASSOCIATION
- AMERICAN SOCIETY FOR COLPOSCOPY AND CERVICAL PATHOLOGY
- AMERICAN SOCIETY FOR CYTOPATHOLOGY
- AMERICAN SOCIAL HEALTH ASSOCIATION
- NATIONAL ASSOCIATION OF NURSE PRACTITIONERS IN WOMEN'S HEALTH

Advances in Cervical Cancer Prevention

ARHP's *Clinical Proceedings* CME available online
FREE for ARHP members—www.arhp.org

CLINICAL PROCEEDINGS®

A PUBLICATION OF
ASSOCIATION OF REPRODUCTIVE HEALTH PROFESSIONALS

Endorsed by
AMERICAN CANCER SOCIETY
AMERICAN COLLEGE HEALTH ASSOCIATION
AMERICAN MEDICAL WOMEN'S ASSOCIATION
AMERICAN SOCIETY FOR COLPOSCOPY AND CERVICAL PATHOLOGY
AMERICAN SOCIETY FOR CYTOPATHOLOGY
AMERICAN SOCIAL HEALTH ASSOCIATION
NATIONAL ASSOCIATION OF NURSE PRACTITIONERS IN WOMEN'S HEALTH

September 2003

Advances in Cervical Cancer Prevention

3
INTRODUCTION

4
HPV INFECTION AND CERVICAL INTRAEPITHELIAL NEOPLASIA

9
RECENT DEVELOPMENTS IN CERVICAL CANCER SCREENING

10
CURRENT RECOMMENDATIONS FOR PRIMARY SCREENING

11
MANAGEMENT OF THE ABNORMAL PAP

16
COUNSELING PATIENTS WITH HPV

19
NEW DEVELOPMENTS IN CERVICAL CANCER SCREENING AND TREATMENT

19
CONCLUSIONS

ARHP *Clinical Proceedings*® is a publication of the Association of Reproductive Health Professionals (ARHP). The publishers reserve copyright on all published materials, and such material may not be reproduced in any form without the written permission of ARHP.

This publication is intended for physicians, nurse practitioners, nurse midwives, registered nurses, pharmacists, physician assistants, researchers, public health professionals, researchers, and health educators in the field of reproductive health.

ARHP is a non-profit, 501(c)(3) educational organization with a membership of obstetrician/gynecologists and other physicians, advanced practice clinicians, researchers, educators, and other professionals in reproductive health.

Please direct all inquiries to:
ARHP
2401 Pennsylvania Avenue, NW, Suite 350
Washington, DC 20037-1718 USA
Phone: (202) 466-3825 ◆ Fax: (202) 466-3826
E-mail: arhp@arhp.org ◆ Web: www.arhp.org

Accreditation

Instructions for receiving a continuing education certificate for this program are on the back cover.

Physicians—ARHP is accredited by the Accreditation Council for Continuing Medical Education (ACCME) to sponsor continuing medical education (CME) for physicians. ARHP designates this continuing medical education activity for **two** (2) credit hours in Category One of the Physician's Recognition Award of the American Medical Association.

Nurses and Nurse Practitioners—This educational activity has been approved by the Continuing Education Approval Program of the National Association of Nurse Practitioners in Women's Health (NPWH) for **2.4** contact hours, including **0.8** pharmacology hours. Credit can be applied toward the nursing continuing education requirements of most professional organizations and State Boards of Nursing.

Nurse Midwives—ACCME credit hours in Category One are accepted by the Continuing Competency Assessment Program of the American College of Nurse Midwives (ACNM) for programs relevant to nurse midwifery.

Physician Assistants—The American Academy of Physician Assistants accepts Category One CME approval from organizations accredited by the ACCME.

New Developments in Cervical Cancer Screening Complement the Traditional Pap Test

Cervical cancer remains the third most common cancer among women in the US, and is diagnosed in 13,000 women each year in the US. While the mortality rate has decreased significantly since the advent of the Papanicolaou (Pap) smear in the 1940s, almost half of all women who develop cervical cancer have not received proper screening. Human papillomavirus (HPV) infection has been implicated as a chief risk factor for cervical cancer; HPV DNA is found in over 93% of these carcinomas.

Recent developments in the field of cervical cancer screening, including liquid-based cervical cytologic testing and HPV DNA testing, have significant implications for the screening and management of cervical epithelial abnormalities. For example, with the introduction of HPV DNA testing, women and their clinicians have an objective measure of risk, allowing them to be more reassured in the case of a negative result.

We hope this *Clinical Proceedings*®, which updates our 2001 version on the same topic, advances your knowledge of HPV, cervical cancer, and clinical guidelines for cervical cancer screening.

We hope you will find this information useful in your health care practice. Please let us know what you think.

Finally, we are delighted to announce that this publication has received the endorsement of the following key organizations:

- American Cancer Society
- American College Health Association
- American Medical Women's Association
- American Society for Colposcopy and Cervical Pathology
- American Society for Cytopathology
- American Social Health Association
- National Association of Nurse Practitioners in Women's Health

We are grateful for their support.

Sincerely,



Wayne C. Shields

ARHP President and CEO

Learning Objectives

After completing this *Clinical Proceedings*, participants will be able to:

1. Describe the most common genital HPV types in benign and malignant disease.
2. Identify the most common mode of HPV transmission.
3. Describe the natural history of HPV.
4. Understand the natural history of cervical intraepithelial neoplasia.
5. Understand new technological developments in cervical cancer screening and treatment.
6. Discuss the current recommendations for primary screening of cervical cancer.
7. Describe two recent developments in cervical cancer screening.
8. List the three elements of The Bethesda System (TBS) in Pap test reporting.
9. Describe management options for cervical epithelial abnormalities.
10. Understand the psychosocial and counseling issues related to HPV and cervical cancer.

This publication has been made possible by an unrestricted educational grant from Digene Corporation.

INTRODUCTION

Genital infection with human papillomavirus (HPV) is the most common sexually transmitted viral infection in the US.[1] It is estimated that there are as many as five million new infections with HPV each year.[2] Overall, an estimated 75 percent of the adult population has been exposed to HPV (Figure 1).[3] There is also evidence that the rate of HPV infection is increasing.[1] In a study conducted in the United Kingdom, the rate of clinic visits for genital warts increased almost 600 percent for women between 1971 and 1994.[4]

Figure 1: Incidence of HPV Infection



Source Reference 3

The importance of HPV infection has only been recognized by the medical community relatively recently. HPV has long been associated with a number of clinical conditions, such as plantar warts and common warts, but certain types also have the capability for oncogenesis in the cervix.[5] The link between HPV infection and cervical cancer was first recognized in 1975 by Harold zur Hausen, a virologist, who suggested that HPV may be associated with cervical neoplasia.[6] The strength of the association between HPV and cervical cancer is significantly greater than that between smoking and lung cancer.[7,8] Cervical cancer is currently the 13th most common cancer among women in the United States.[9] While death from cervical cancer has been reduced by more than 70 percent since the introduction of the Papanicolaou (Pap) smear in 1943, more than half the women who develop cervical cancer have not received proper screening.[10,11,12] The Pap smear is also associated with a significant false negative rate.[11]

Liquid-based Pap test techniques may address some of the problems associated with conventional Pap test techniques and will be discussed in greater detail in a later section. In addition, the advent of HPV DNA testing provides clinicians with additional information that can help stratify the risk of cervical cancer. HPV testing can be used in addition to cytology for primary screening in women 30 years of age and older, and as triage, or second-level testing, for women of all ages who have an equivocal cytology result. These advances in testing and changes in published guidelines for the management of abnormal findings may help to improve effective screening and increase the number of women accessing early intervention.

1. Bonnez W, Reichman RC. Papillomaviruses. In: Mandell GL, Bennett JE, Dolin R, eds. *Principles and Practice of Infectious Disease. 5th ed.* Philadelphia: Churchill Livingstone, Inc.; 2000.
2. Burd EM. Human papillomavirus and cervical cancer. *Clin Microbiol Rev.* 2003;16(1):1-17.
3. Koutsky LA for the ALTS Group. HPV triage as a management strategy for women with low-grade squamous intraepithelial lesions. *J Nat Cancer Inst.* 2000;92:397-402.
4. Simms I, Fairley CK. Epidemiology of genital warts in England and Wales: 1971 to 1994. *Genitourin Med.* 1997;73:365-7.
5. Brentjens MH, Yeung-Yeu KA, Lee PC, Tyring SK. Human papillomavirus: a review. *Dermatol Clin.* 2002; 20(2): 315-31.
6. Burd EM. Human papillomavirus and cervical cancer. *Clin Microbiol Rev.* 2003;16(1):1-17.
7. Bosch FX, Lorincz A, Munoz N, et al. The causal relation between human papillomavirus and cervical cancer. *J Clin Pathol.* 2002;55:244-65.
8. Franco EL. Cancer causes revisited: human papillomavirus and cervical neoplasia. *J Natl Cancer Inst.* 1995;87:779-80.
9. Jamal A, Murray T, Samuels A, et al. *Cancer statistics, 2003. CA Cancer J Clin.* 2003;53:5-26.
10. Saslow D, Runowicz CD, Solomon D, et al. American Cancer Society guideline for the early detection of cervical neoplasia and cancer. *CA: Cancer J Clin.* 2002;52:342-62.
11. Ball C, Madden JE. Update on cervical cancer screening: current diagnostic and evidence-based management protocols. *Postgrad Med.* 2003;113(2):59-70.
12. Sawaya GF, Brown AD, Washington AE, Garber AM. Clinical practice. Current approaches to cervical-cancer screening. *N Engl J Med.* 2001;344(21):1603-7.

HPV Infection and Cervical Intraepithelial Neoplasia

HPV Types

More than 100 types of HPV have been identified.[1] An HPV type is considered a new type when at least 10 percent of the gene sequences in the HPV regions E6, E7, and L1 differ from any previously known type.[2]

Association with disease

HPV infection has been associated with several clinical manifestations. Cutaneous warts, including plantar, common, and flat warts, are associated with various types of HPV (particularly types 1 and 2) and are benign. These warts, which are usually asymptomatic and self-limited, are not typically found on genital skin. They spontaneously resolve in 90 percent of children within five years.[3] Anogenital warts, or condylomata acuminata, are also associated with HPV infection, generally with types 6 and 11.[1] These lesions are either sessile on the skin or attached by a broad peduncle and range from smooth papules to jagged cauliflower-like growths.[4] HPV can also cause latent or inactive infection, in which infected individuals have no symptoms and the infected area is cytologically and colposcopically normal. Persistent infection with high-risk HPV types can result in various forms of cancer. The virus is most strongly associated with cervical cancer, with HPV DNA found in up to 99.7 percent of these cancers, but it is also associated with other carcinomas, such as vulvar, vaginal, anal, penile, and oropharyngeal cancers.[5,4]

The most common human papillomavirus types associated with selected conditions are listed in Table 1.

High versus low risk

HPV types have been divided into high and low risk, based on their association with cervical carcinoma and precursor lesions. The most common low-risk types include 53, 61, 62, and 71. Low-risk types 6 and 11 are associated with external genital warts. Types 16, 18, 26, 31, 33, 35, 39, 45, 51, 52, 56, 58, 59, 66, 68, 73, and 82 are considered high-risk types, because they have been associated with cervical cancer or squamous intraepithelial lesions. Highest risk is associated with types 16 and 18, which cause approximately 75 percent of cervical cancers.[6,7]

Transmission and Natural History of HPV Infection

HPV is generally transmitted via skin-to-skin contact, most commonly during sexual activity. It is rarely transmitted non-sexually. After transmission, the virus either is cleared by the immune system (or suppressed below the limits of detection) or causes persistent infection.

Transmission of HPV

Sexual transmission. HPV is easily transmitted by genital-to-genital contact. The period between exposure and the identification of a specific lesion is extremely variable, making it virtually impossible for most individuals to determine exactly when and from whom HPV exposure occurred.

Table 1: The most common genital and non-genital HPV types in benign and malignant disease

	CASES		CONTROLS			
HPV type	No	%	No	%	OR (95% CI)*	
negative	46	3.39	1091	84.44	1.00	
HPV 16	685	50.52	42	3.25	434.34	(278.30-677.87)
HPV 18	177	13.05	17	1.32	248.56	(138.37-446.48)
HPV 31	36	2.65	8	0.62	122.16	(52.87-282.26)
HPV 33	14	1.03	1	0.08	368.34	(46.15-2939.53)
HPV 35	15	1.11	6	0.46	74.99	(26.82-209.72)
HPV 39	8	0.59	0	0	-	
HPV 45	74	5.46	9	0.7	197.46	(91.69-425.26)
HPV 51	13	0.96	4	0.31	65.65	(19.76-218.12)
HPV 52	37	2.73	4	0.31	198.99	(67.49-586.72)
HPV 56	9	0.66	5	0.39	45.24	(14.05-145.63)
HPV 58	31	2.29	6	0.46	115.64	(45.40-294.57)
HPV 59	17	1.25	1	0.08	418.60	(54.15-3236.17)
HPV 73	5	0.37	1	0.08	107.28	(11.52-999.43)

Extragenital and fomite transmission. HPV can be spread via contact with infected labial, scrotal, or anal tissues, thus reducing the effectiveness of condoms to prevent infection.[2] Fomite transmission is rare.[8] HPV is relatively resistant to heat; it has been shown to resist heat at 56° C for one hour, but is killed by autoclaving.[8]

Figure 2: Natural History of HPV Infection When Active Expression Occurs

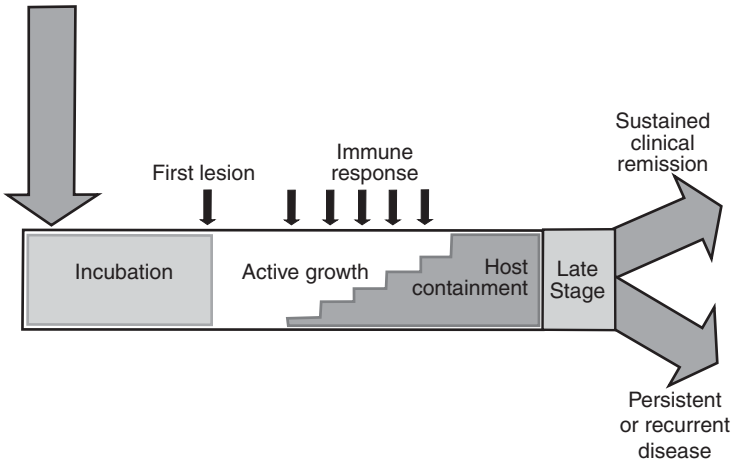

HPV virus has also been shown to be present in the smoke plume generated by carbon dioxide laser treatment of genital lesions.[9]

Vertical transmission. Invasive squamous cell cervical cancer is non-existent in individuals who have not had

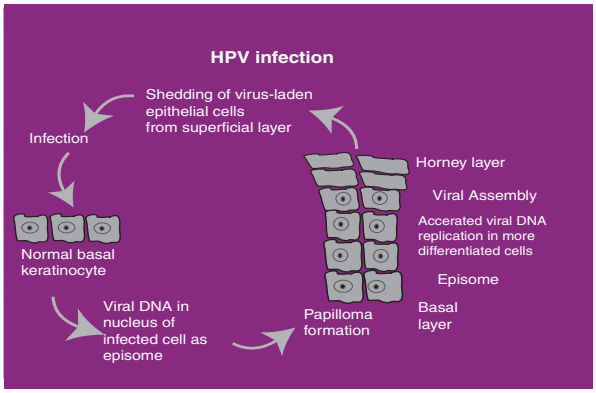

Figure 3: The viral LIFE cycle, used with permission from Dr. J. Thomas Cox.

sexual contact. This indicates either that genital colonization at the time of birth with oncogenic HPV does not occur, or that the unfavorable hormonal milieu present in the neonate after clearance of maternal estrogen and progesterone does not favor HPV persistence and lesion expression. The only clinically expressed HPV disease known to be acquired at birth is respiratory papillomatosis secondary to transmission of HPV 6 or 11 from mother to infant at the time of birth; this condition is rare.[4]

Natural history of HPV

The natural history of HPV begins with infection, followed by a variable period of time during which no disease expression is present. Later there may be a phase of active growth and a final phase of host-containment (see Figure 2). Most HPV infections do not result in detected cellular changes, genital warts, cervical intraepithelial neoplasia (CIN), or cervical cancer.[11,12,13] If HPV infection is not contained, due to host, viral, and environmental factors, a phase of active growth will manifest in one or more of these morphologic expressions. For the majority of patients, a phase of host containment begins following immune recognition of the presence of HPV. A successful immune response results in viral control (latency) or clearance. A minority of individuals do not develop adequate host containment and are at risk for HPV persistence. The persistence of high-risk HPV infection is necessary for the development of precursor lesions and cervical carcinoma.[6]

The most basic segments of the natural history of transient HPV infection include viral entry, viral replication, productive viral infection, and host containment. The viral life cycle is depicted in Figure 3.

Viral entry. The first step in HPV infection is entry into the host cell. HPV first enters the basal cells in the stratum germinativum, or basal layer, of the epithelium.[2] The virus is usually transmitted via skin-to-skin contact, and often enters in sites of microtrauma, most commonly found in the female at the introitus and perineum following sexual activity. Other areas with increased vulnerability for HPV infection are the epithelial layers of immature metaplasia found in the transformation zone of the cervix and anal verge.

Viral replication. Papillomaviruses are small, double-stranded DNA viruses encased in a protein capsid. To enter the host cell, HPV must shed its protein capsid, injecting naked DNA into the cytoplasm of the cell. From the cytoplasm, the DNA travels to the cell nucleus. The viral genome usually exists in an episomal (circular) configuration that can be divided into three regions: the long control region (LCR), the early region (E), and the late region (L).[2] (See Figure 4.) The LCR is responsible for regulation of viral replication and controls transcription of some sequences in the early region. The early region encodes predominantly for proteins that are important in viral replication, which occurs "early" in the viral life cycle. The late region encodes for viral structural proteins that are necessary for capsid production, which occurs "late" in the viral life cycle.[2]

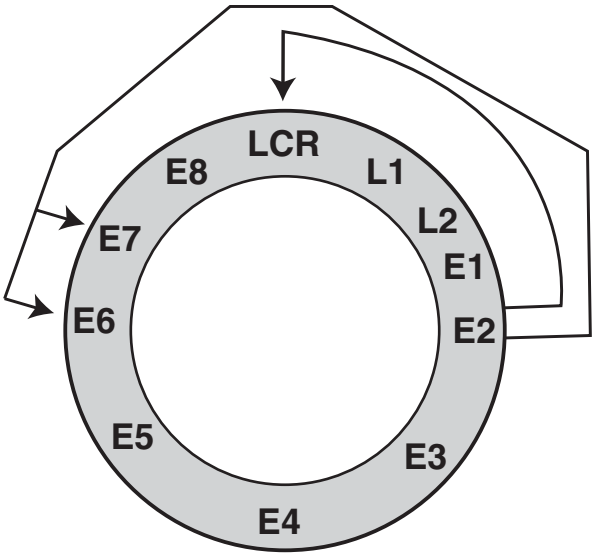

Figure 4: HPV DNA. Most HPV exists in an episomal (circular) DNA. The important genomic sites are called open reading frames (ORFs). In the episomal state, E2 regulates both the long control region (LCR), which is responsible for regulation of viral transcription, and E6 and E7, the two sites most responsible for malignant transformation.

The early region has eight different regions that encode for proteins that play vital roles in the HPV life cycle. Two of these regions, designated E6 and E7, are crucial in the process of oncogenesis in high-risk types of HPV. The E6 protein binds to the p53 tumor suppressor gene product and accelerates its destruction. The E7 protein binds to the retinoblastoma protein (pRb), another tumor suppressor gene product, inhibiting its function.[4] The actions of the E6 and E7 proteins lead to cellular transformation.[2] Laboratory study has shown that low-risk HPVs have a much lower capacity to induce malignant transformation *in vitro* than do high-risk HPVs because of functional differences between their E6 and E7 proteins.[2] For example, the E6 proteins of low-risk HPV bind to the protein product of p53 poorly, and thus are less able to transform infected cells.[2] The two late regions, L1 and L2, encode for proteins involved in construction of the capsid of the infective HPV genome.

In benign lesions associated with HPV, viral DNA exists as a circular extrachromosomal DNA in the nucleus. However, in cancerous cells and in some precancerous lesions associated with HPV, the viral DNA is integrated into the host genome. Generally, the integration of the viral DNA deletes or disrupts the E2 region, resulting in loss of normal E2 down-regulation of E6 and E7, which leads to increased expression of these two regions. E6 and E7 proteins from high-risk HPV types bind to p53 and pRb, disrupting the normal function of these proteins and inducing increased cell proliferation, genomic instability, and accumulation of mutations, which ultimately may lead to fully transformed cancer cells.[2]

Productive viral infection. At some point, daughter cells of the infected basal cells may begin to carry transcriptionally active episomal HPV DNA. As these cells differentiate and mature, HPV replicates, making 50 to 100 replicated copies per cell. Activation of the L1 region of the HPV genome in the upper epithelial layers envelopes each episomal DNA in a protein capsid, recreating the infective unit. HPV induction of cytoplasmic proteins in some of the infected epithelial cells results in the hallmark cell of HPV infection, the koilocyte. Koilocytes are large, polygonal squamous cells with a wrinkled nucleus and a large perinuclear cavity.[4] (See Figure 5.) Shedding of the dead keratinocytes as part of the natural process of the cell cycle releases HPV virions to infect other cells or transmit the virus to another individual.

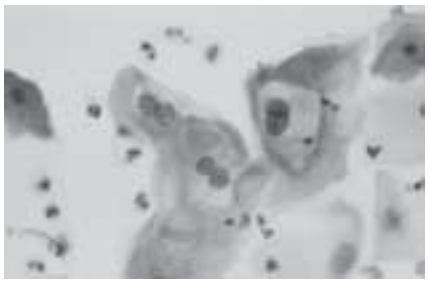

Figure 5: Koilocytes are HPV-infected cells with irregular-shaped nuclei pushed to the side by HPV-induced cytoplasmic proteins. These cells are pathognomonic for HPV infection.

In productive infection, viral replication is associated with proliferation of all layers except the basal layer.[2] In high-grade CIN, viral replication is associated with proliferation of the cells in the basal layer and with an increased number of mitoses, some of which are abnormal.[2] The exact factors that determine the transition from productive infection to persistent infection associated with high-grade lesions are unknown, but a complex interplay of host, viral, and environmental factors is most likely important.

Host containment. Recognition of the presence of HPV by the immune system results in a T-cell response. T cells are the primary effectors of the cellular immune response, which is known to be of prime importance in limiting HPV infection.[13] The humoral immune system may also be involved with fighting HPV infection and preventing reinfection with the same HPV type. Antibodies against the viral capsid have been detected in individuals with cutaneous or urogenital warts.[14,15,16]

In most cases, genital HPV infection appears to be transient. In one study of college women, the median duration of HPV detection by sensitive molecular tests was eight months; this may be an underestimate because it was not possible to document when these infections began.[10] Other studies have documented a longer duration of detection of HPV that is type-specific, with a mean duration of 13.4 months for low-risk types and 16.3 months for high-risk types.[17] Ninety percent of HPV infections will be cleared or suppressed below the limits of detection by host defenses within one to two years.[11]

Viral persistence is necessary for HPV-induced oncogenesis to occur. Persistent infection with high-risk HPV types correlates with age and high viral load and is associated with increased risk of CIN.[18,19,10] In a two-year study, CIN lesions were 11 times more likely to develop in women with infection at baseline caused by HPV type 16 or 18 than in women without HPV infection at baseline.[20]

Consequences of Genital HPV Infection

The clinical consequences of genital HPV infection depend on viral type and the host immune response, and include formation of condylomata, intraepithelial neoplasia, or cancer throughout the lower genital tract. Genital warts are most commonly found in the posterior introitus, labia majora and minora, perineum, and clitoris in females. Other common sites include the vagina, anus, cervix, and urethra. In males, genital warts are most commonly found on the penile shaft in circumcised males and the preputial cavity in uncircumcised males.[4] Diagnosis of external genital HPV lesions is not always straightforward. Normal papillary tissue in the vestibule of the female and just under the corona of the penis in the male (pearly penile papules) is often confused with HPV disease (see Figure 6 a,b).

Figure 6a: Normal micropapillae in the vestibule

Figure 6b: Normal papillations under the penile corona

Genital warts are most commonly flesh- to gray-colored and vary from smooth, pearly papules to jagged, acuminate growths.[4] On keratinized skin, condylomata are typically exophytic, white, gray or flesh-colored warty lesions (Figure 7), whereas on mucosa, these lesions are likely to have finger-like papillary projections and to be closer in color to the surrounding skin (Figure 8 a,b).

In contrast to external genital warts, or condylomata acuminata, which are usually easily seen with the naked eye, HPV disease on the cervix usually requires magnification and acetic acid application for identification. Approximately 10 percent of women have HPV DNA despite cytologically normal cervical epithelium.[2] Such subclinical HPV disease may be found in all areas of the lower genital tract of both males and females.



Figure 7: Typical exophytic condyloma acuminta on keratinized skin superior to the clitoris.

Cervical cancer and its precursor lesion will be discussed in greater detail in the following sections. For more information about the management of external genital warts, please refer to Centers for Disease Control and Prevention, *Sexually Transmitted Diseases Treatment Guidelines 2002*. MMWR 2002:51 (No. RR-6): 53-7. (Available at http://www.cdc.gov/mmwr/preview/mmwrhtml/rr5106a1.htm.)

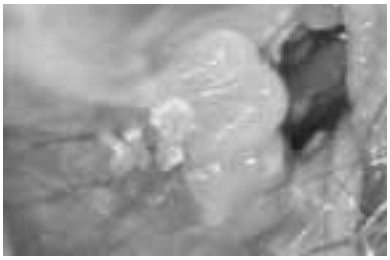

Figure 8a: Tiny exoplytic condyloma near the vestibular gland opening at the hymenal ring.

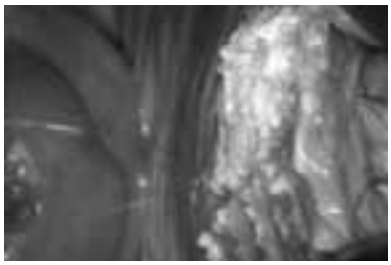

Figure 8b: Exoplytic condyloma on the left vaginal wall.

Natural History of Cervical Intraepithelial Neoplasia

Persistence of DNA from a high-risk HPV type is significantly associated with development of high-grade cervical dysplasia and cervical cancer.[11,21] Cervical carcinoma and its high-grade precursor lesion, CIN 3, are most commonly found at the junction between the squamous and glandular cells, which is called the *squamocolumnar junction* (SCJ). The cervical transformation zone, an active area of metaplasia at the SCJ, is especially vulnerable to HPV-induced cellular transformation (see Figure 9).

After infection with HPV, one of two clinical scenarios may occur: transient viral expression with clinical clearance or viral persistence. Most infections remain undetectable or produce transient cytologic changes that are missed by infrequent screening. Other infections cause detectable cytologic changes diagnostic

Figure 9: Cervical transformation zone. The transformation zone lies between the new squamocolumnar junction (SCJ) and the original squamocolumnar junction (OSCJ) as noted by arrow in this picture and represents advancing metaplasia. The new squamocolumnar junction is defined by the leading edge of squamous cells as they abut the columnar epithelium. The mildly acetowhite area within this transformation zone is a low-grade HPV lesion. This patient was referred to colposcopy for a low-grade squamous intraepithelial lesion (LSIL) Pap.

of HPV infection, including low-grade squamous intraepithelial lesion (LSIL) or high-grade squamous intraepithelial lesion (HSIL), or induce the shedding of cells that demonstrate only some, but not all, of the features of an HPV infection (e.g., atypical squamous cells of undetermined significance or ASC-US) (see Figure 10).

CIN is a tissue-based classification. The designation of CIN 1, 2, or 3 is based on thickness of the epithelium showing abnormal cells, the degree of mitotic activity, and nuclear atypia.[22] CIN 1 and 2 correspond to mild and moderate dysplasia, respectively; CIN 3 is analogous to severe dysplasia or carcinoma-in-situ. Pathologists often disagree about the interpretation of samples at the lower end of the cytologic and histologic spectra (ASC-US and CIN 1, respectively).[23]

The disparity between the high rate of infection with HPV and the relatively low risk of cervical cancer reflects the fact that many women become infected with HPV, but most infections spontaneously regress over time. Attempts to understand why the virus persists in some women have focused on variants of high-risk HPV types and cofactors such as smoking, other infectious agents (chlamydia, herpes, bacterial vaginosis), parity, use of oral contraceptives, and host immune factors. In the end, any important role played by HPV variants and cofactors is likely to be due to the promotion of viral persistence, because it is the most important factor in determining whether an HPV infection has the potential to progress to develop into a precancerous lesion or cancer.

The incidence of invasive cervical cancer reaches a plateau in women approximately 15 years later than the peak incidence of CIN 3, suggesting a slow progression from CIN 3 to invasive carcinoma.[24,25] This prolonged period from development of CIN 3 to invasion probably reflects the long period of time required for the accumulation of mutations following viral integration and down-regulation of the apoptotic functions of p53 and pRb. The inhibition p53 and pRb leads to an increased cell proliferation rate and to genomic instability. The infected cell acquires more and more DNA damage that cannot be repaired, leading eventually to oncogenic transformation.

Figure 10: Management of Women with Atypical Glandular Cells (AGC)

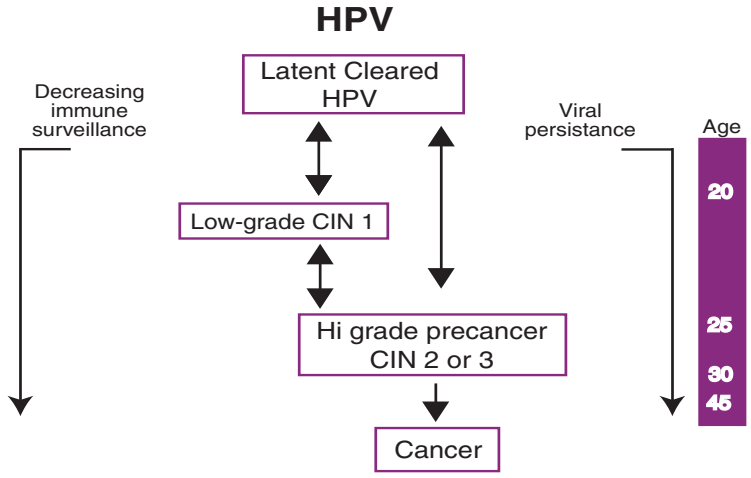

1. Brentjens MH, Yeung-Yeu KA, Lee PC, Tyring SK. Human papillomavirus: a review. *Dermatol Clin.* 2002; 20(2): 315-31.
2. Burd EM. Human papillomavirus and cervical cancer. *Clin Microbiol Rev.* 2003;16(1):1-17.
3. Massing AM, Epstein WL. Natural history of warts: a two-year study. *Arch Dermatol.* 1963;87:306-310.
4. Bonnez W, Reichman RC. Papillomaviruses. In: Mandell GL, Bennett JE, Dolin R, eds. *Principles and Practice of Infectious Disease. 5th ed.* Philadelphia: Churchill Livingstone, Inc.; 2000.
5. Walboomers JMM, Jacobs MV, Manos MM, et al. Human papillomavirus is a necessary cause of invasive cervical cancer worldwide. *J Pathol.* 1999;189:12-9.
6. Bosch FX, Lorincz A, Munoz N, et al. The causal relation between human papillomavirus and cervical cancer. *J Clin Pathol.* 2002;55:244-65.
7. Munoz N, Bosch FX, de Sanjose S, et al. International Agency for Research on Cancer Multicenter Cervical Cancer Study Group. Epidemiologic classification of human papillomavirus types associated with cervical cancer. *N Engl J Med.* 2003;348(6):518-27.
8. Roden RB, Lowy DR, Schiller JT. Papillomavirus is resistant to desiccation. *J Infect Dis.* 1997;176:1076-9.
9. Sawchuk WS, Weber PJ, Lowy DR, et al. Infectious papillomavirus in the vapor of warts treated with carbon dioxide laser or electrocoagulation: Detection and protection. *J Am Acad Dermatol. 1989*;21:41-49.
10. Ho GY, Bierman R, Beardsley L, et al. Natural history of cervicovaginal papillomavirus infection in young women. *N Engl J Med.* 1998;338:423-8.
11. Moscicki AB, Shiboski S, Broering J, et al. The natural history of human papillomavirus infection as measured by repeated DNA testing in adolescent and young women. *J Pediatr.* 1998;132:277-84.
12. Hildesheim A, Schiffman MH, Gravitt PE, et al. Persistence of type-specific human papillomavirus infection among cytologically normal women. *J Infect Dis.* 1994;169:235-40.
13. Oguchi M, Komura J, Tagami H, et al. Ultrastructural studies of spontaneously regressing plane warts: macrophages attack verruca-epidermal cells. *Arch Dermatol Res.* 1981;270:403-11.
14. Kienzler JL, Lemoine MT, Orth G, et al. Humoral and cell-mediated immunity to human papillomavirus type 1 (HPV-1) in human warts. *Br J Dermatol.* 1983;108:665-72.

15. Bonnez W, DaRin C, Rose RC, et al. Use of human papillomavirus type 11 virions in an ELISA to detect specific antibodies in humans with condylomata acuminata. *J Gen Virol.* 1991;72:1343-7.

16. Bonnez W, Kashima HK, Leventhal B, et al. Antibody response to human papillomavirus (HPV) type 11 in children with juvenile-onset recurrent respiratory papillomatosis. *Virology.* 1992;188:384-7.

17. Richardson H, Kelsall G, Tellier P, et al. The natural history of type-specific human papillomavirus infections in female university students. *Cancer Epidemiol Biomarkers Prev.* 2003;12(6):485-90.

18. Brown DR, Rawlings K, Handy V, et al. Human papillomavirus detection by Hybrid Capture in paired cervicovaginal lavage and cervical biopsy specimens. *J Med Virol.* 1996;48:210-14.

19. Londesborough P, Ho L, Terry G, et al. Human papillomavirus genotype as a predictor of persistence and development of high-grade lesions in women with minor cervical abnormalities. *Int J Cancer.* 1996;69:364-8.

20. Koutsky LA, Holmes KK, Critchlow CW, et al. A cohort study of the risk of cervical intraepithelial neoplasia grade 2 or 3 in relation to papillomavirus infection. *N Engl J Med.* 1992;327:1272-8.

21. Nobbenhuis MAE, Walboomers JMM, Helmerhorst TJM, et al. Relation of human papillomavirus status to cervical lesions and consequences for cervical-cancer screening: a prospective study. *Lancet.* 1999;354:20-5.

22. Eifel PJ, Verek JS, Thigpen JT. Cancer of the cervix, vagina, and vulva. In: DeVita VT, Jr, Hellman S, Rosenberg SA, eds. *Cancer: Principles and Practice of Oncology. 6th ed.* Philadelphia: Lippincott Williams & Wilkins; 2001.

23. Stoler MH, Schiffman M. Atypical Squamous Cells of Undetermined Significance-Low-grade Squamous Intraepithelial Lesion Triage Study (ALTS) Group. Interobserver reproducibility of cervical cytologic and histologic interpretations: realistic estimates from the ASCUS-LSIL Triage Study. *JAMA.* 2001;285(11):1500-5.

24. Kivlahan C, Ingram E. Papanicolaou smears without endocervical cells: are they inadequate? *Acta Cytol.* 1986;30:258.

25. Walton RJ. Editorial: the task force on cervical cancer screening programs. *Can Med Assoc J.* 1976;114:981.

Recent Developments in Cervical Cancer Screening

There have been two recent important developments in cervical cytologic screening and the management of abnormal Pap test results: liquid-based Pap tests and HPV DNA testing.

Liquid-based Pap tests. Liquid-based, thin-layer preparation techniques have been developed in an attempt to reduce false-negative rates associated with conventional Pap tests and thereby improve the sensitivity of Pap tests in detecting abnormalities.[1] Cells collected by the clinician are suspended in a liquid medium. In the laboratory, the cells are applied to a glass slide as a thin cellular layer by a processor, removing much of the mucus, blood, and inflammatory cells. There are currently two FDA-approved liquid-based cytology methods: the Sure-Path® system (TriPath Imaging Inc., Burlington, North Carolina) and the ThinPrep® Pap Test™ (Cytyc Corp., Boxborough, Massachusetts). Liquid-based cytology methods are more expensive than conventional Pap tests but are supported by data demonstrating improved diagnostic sensitivity.[2,3,4]

HPV DNA Testing. The three primary methods for detecting HPV DNA are type-specific polymerase chain reaction (PCR), which typically assays sequence variations in L1 late capsid gene of anogenital HPV types; general primer PCR, which amplifies a spectrum of HPV types and targets conserved regions of the HPV genome; and liquid hybridization, which uses chemoluminescence to detect the presence of HPV. Only one test—a liquid hybridization method called Hybrid Capture (Digene, Gaithersburg, Maryland)—is currently FDA-approved for the detection of HPV DNA in cervical samples. The test uses two probe cocktails: one for high-risk HPV types, the other for low-risk types. Recent management guidelines recommend the use of the high-risk panel only, because only high-risk types are associated with cervical carcinoma.[5] The second-generation liquid hybridization test, called Hybrid Capture 2 (hc2), has been extensively studied and is now widely available for use in clinical laboratories.

There are two recommended uses for HPV DNA testing: as primary screening in combination with Pap test for women 30 years of age and older and as triage for women of all ages who have an equivocal cytology result.[6,7]

The next section will describe the role of HPV testing in primary cervical screening. The subsequent section will review its use for triage for women with an equivocal cytology result.

1. Ball C, Madden JE. Update on cervical cancer screening: current diagnostic and evidence-based management protocols. *Postgrad Med.* 2003;113(2):59-70.

2. Austin RM, Ramzy I. Increased detection of epithelial cell abnormalities by liquid-based gynecologic cytology preparations. A review of accumulated data. *Acta Cytol.* 1998 Jan-Feb;42(1):178-84.

3. Lee KR, Ashfaq R, Birdsong GG, et al. Comparison of conventional Papanicolaou smears and a fluid-based, thin-layer system for cervical cancer screening. *Obstet Gynecol.* 1997;90(2):278-84.

4. Vassilaskos P, Saurel J, Rondez R. Direct-to-vial use of the AutoCyte PREP liquid-based preparation for cervical-vaginal specimens in three European laboratories. *Acta Cytol.* 1999;43:65-8.

5. Wright TC, Jr., Cox JT, Massad LS, Twiggs LB, for the 2001 ASCCP-Sponsored Consensus Conference. 2001 consensus guidelines for the management of women with cervical cytological abnormalities. *JAMA*. 2002;287(16):2120-9.

6. Sherman ME, Lorincz AT, Scott DR, et al. Baseline cytology, human papillomavirus testing, and risk for cervical neoplasia: a 10-year cohort analysis. *J Natl Cancer Inst.* 2003;95(1):46-52.

7. ALTS Group. Results of a randomized trial on the management of cytology interpretations of atypical squamous cells of undetermined significance. *Am J Obstet Gynecol.* 2003a;188:1383-92.

Current Recommendations for Primary Screening

Both the American Cancer Society (ACS) and the new American College of Obstetricians and Gynecologists (ACOG) guidelines recommend that cervical cancer screening begin three years after a woman begins having vaginal intercourse but no later than age 21.[1,2] ACS recommends that screening be conducted every two years if a liquid-based Pap test is used, or annually if conventional cytology is used. ACOG recommends screening annually in women younger than 30 regardless of the type of Pap performed. Both guidelines also recommend that women 30 years of age and older with three consecutive technically satisfactory, normal results can reduce frequency of testing to once every two to three years. Women at higher risk for cervical cancer, such as women with human immunodeficiency virus (HIV) infection, should be screened more often.

The ACS guidelines for primary screening were published before the FDA approval of the Hybrid Capture 2 (hc2) test for screening, but they included the note that upon approval, HPV DNA testing would be reasonable for screening of women 30 years of age and older, when used with either conventional or liquid-based cytologic testing.[1] The guidelines recommend that women testing negative on both Pap and HPV tests not be rescreened more often than every three years.[1] The ACOG guidelines, which were published after FDA approval of hc2, also recommend rescreening after negative/negative results no more frequently than every three years.[2]

An evaluation of 4,075 women attending a women's health clinic found that hc2 was less specific (72.6 percent versus 82.4 percent), but more sensitive (90.8 percent versus 61.3 percent) than liquid-based Pap test for identifying women with CIN 3 or higher.[3] A large-scale study of more than 20,000 women who were members of a health maintenance organization found that the risk of CIN 3 or invasive cervical carcinoma in the 45-month follow-up period after an initial Pap/HPV DNA test was much higher among women with positive Pap tests (atypical squamous cells or worse) or positive HPV DNA tests, or both positive Pap and HPV DNA tests, compared with women with negative results for both tests (4.54 percent versus 0.16 percent).[4] The decreased risk associated with a negative/negative result was primarily due to the very high negative predictive value of the negative HPV test result. A negative Pap test combined with a negative HPV DNA test predicts the absence of CIN 3 or cervical carcinoma with a certainty of approximately 99.21 percent.[4] This level of certainty is novel; clinicians have not previously been able to offer women such high assurance of the absence of high-grade CIN or cancer.

The combined use of Pap and HPV DNA testing improves the ability of clinicians to quantify a woman's risk of cervical carcinoma or its precursor lesion. In simplified terms, the Pap test provides an assessment of present risk, whereas HPV DNA testing provides a measure of not only present but also future risk, thus informing decisions about the timing of retesting. The increased reassurance of a negative/negative test result provides increased reassurance for a screening interval of every three years. In summary, combined Pap/HPV testing can be used for primary screening in women 30 years of age and older, with rescreening no more frequently than every three years after a negative/negative result. Combined Pap/HPV testing is

not recommended for primary screening in women under 30 years of age, because of the high rate of HPV infection, most of which is transient, in this age group.[2]

Table 2 shows the four possible outcomes of combined Pap/HPV testing in primary screening, and the management implications.

The implications of the recent changes in recommendations are significant. The combined use of Pap and HPV DNA testing in women 30 and older, will require educating women that a three year screening interval is appropriate given the very high reassurance provided by negative pap/negative HPV test results (more frequent combined screening could actually be detrimental due to over-referral and over-treatment).

Many women misunderstand the role of the Pap test, viewing it as a test for all gynecological cancers. Women need to be educated at the initiation of cervical screening that the Pap test screens for cervical and vaginal cell changes that are secondary to HPV. Both patients and clinicians will need to distinguish cervical screening from other preventive health care needs, such as breast and pelvic bimanual examinations, that may need to continue on an annual basis.

1. Saslow D, Runowicz CD, Solomon D, et al. American Cancer Society guideline for the early detection of cervical neoplasia and cancer. *CA: Cancer J Clin.* 2002;52:342-62.
2. American College of Obstetricians and Gynecologists. Cervical cytology screening. *ACOG Practice Bulletin No. 45.* 2003;45:1-11.
3. Kulasingam SL, Hughes JP, Kiviat NB, et al. Evaluation of human papillomavirus testing in primary screening for cervical abnormalities: comparison of sensitivity, specificity, and frequency of referral. *JAMA*. 2002;288(14):1749-57.
4. Sherman ME, Lorincz AT, Scott DR, et al. Baseline cytology, human papillomavirus testing, and risk for cervical neoplasia: a 10-year cohort analysis. *J Natl Cancer Inst*. 2003;95(1):46-52.
5. Wright TC, Jr., Cox JT, Massad LS, Twiggs LB, for the 2001 ASCCP-Sponsored Consensus Conference. 2001 consensus guidelines for the management of women with cervical cytological abnormalities. *JAMA*. 2002;287(16):2120-9.
6. Dr. J. Thomas Cox, personal communication, 8/26/03.

Table 2: Management Based on Pap Test and HPV DNA Testing

PAP RESULT	HPV DNA TESTING	
	Positive	Negative
Negative for intraepithelial neoplasia (normal)	Pap and HPV DNA testing in 6 to 12 months	Pap and HPV DNA testing in 3 years
ASC-US	Colposcopy	Repeat Pap in 12 months (possibly with repeat HPV DNA testing)
All other abnormalities: ASC-H AGC LSIL HSIL	Manage per ASCCP Guidelines (available at http://www.asccp.org)	

(Sources: Reference 5 and 6)

Abbreviations: ASC-US: atypical squamous cells of undetermined significance; ASC-H: atypical squamous cells—cannot exclude HSIL; AGC: atypical glandular cells; LSIL: low-grade squamous intraepithelial lesion; HSIL: high-grade squamous intraepithelial lesion; ASCCP: American Society for Colposcopy and Cervical Pathology.

Management of the Abnormal Pap

Appropriate management of an abnormal Pap test result is based on an assessment of the type of cervical epithelial abnormality reported; patient-related factors such as age, postmenopausal status, and reliability for follow-up; and, increasingly, on the presence or absence of high-risk HPV types. The development of liquid-based Pap tests and the recent availability of HPV DNA testing have improved cervical cytologic screening and translated into important changes in the management of cervical epithelial abnormalities.

The Bethesda System

The Bethesda System was first developed in 1988 to unify the terminology used for the results of cervical cytology, thereby aiding clinical management of abnormal Pap test results. The Bethesda System was updated in 1991 and again in 2001. The 2001 Bethesda System maintains the same three general reporting elements: specimen adequacy, general categorization, and interpretation/result (see Table 3).

Table 3: The 2001 Bethesda System (Abridged)

Specimen Adequacy
Satisfactory for evaluation
Unsatisfactory for evaluation
General Categorization (optional)
Negative for intraepithelial lesion or malignancy
Epithelial cell abnormality
Other
Interpretation/Result
Negative for intraepithelial lesion or malignancy
Epithelial cell abnormalities
Squamous cell
Atypical squamous cells of undetermined significance (ASC-US)
Atypical squamous cells—cannot exclude HSIL (ASC-H)
Low-grade squamous intraepithelial lesion (LSIL)
High-grade squamous intraepithelial lesion (HSIL)
Squamous cell carcinoma
Glandular cell
Atypical glandular cells (AGC)
Atypical glandular cells, favor neoplastic
Endocervical adenocarcinoma in situ (AIS)
Adenocarcinoma
Other

Source: see reference 1

Key changes adopted in the 2001 Bethesda System include the removal of the specimen adequacy category "satisfactory but limited by…" because of confusion and unnecessary repeat testing, and the adoption of the term "atypical glandular cells" (AGC) in place of the term "atypical glandular cells of undetermined significance" (AGUS), which had been confused with ASC-US.[1]

Comprehensive guidelines for the management of cervical cytologic abnormalities developed by the American Society for Colposcopy and Cervical Pathology (ASCCP) based on the 2001 Bethesda System were published in 2002.[2] The following sections describe four types of epithelial cell abnormalities outlined by the Bethesda System (excluding squamous cell carcinoma, endocervical adenocarcinoma in situ, and adenocarcinoma) and the management of these abnormalities based on the 2002 management guidelines.[2]

Atypical Squamous Cells of Undetermined Significance

Bethesda System terminology. The 2001 Bethesda System designates two subcategories within the category of "atypical squamous cells": atypical squamous cells of undetermined significance (ASC-US) and atypical squamous cells—cannot exclude HSIL (ASC-H). The term ASC-US retains "undetermined significance" because some cases of ASC-US represent underlying CIN 2/3. The term *ASC-H* highlights the situation in which the cellular changes suggest a high-grade lesion but a definitive interpretation is not possible. The risk of an ASC-H Pap result representing underlying CIN 2/3 is intermediate between those of ASC-US and HSIL.[3] Approximately 5 percent to 10 percent of ASC cases fall into the subcategory of ASC-H.[3,4,5]

The risk of biopsy-proven CIN 2/3 is approximately 15 percent in women with cervical cytology interpreted as ASC,[6] but a large portion of women with ASC-H—24 percent to 94 percent—have CIN 2/3.[2] Women with ASC-H need colposcopy, whereas women with ASC-US need additional evaluation that does not necessarily include immediate colposcopy. For women with ASC-US, it is important to consider the avoidance of unnecessary inconvenience, anxiety, and cost, because the vast majority of women with ASC-US do not have underlying high-grade disease. Immunosuppressed women with ASC-US are at greater risk for CIN 2/3[2] and require immediate colposcopy.

Management. Three management options have been proposed for the follow-up of women with ASC-US: accelerated repeat Pap, immediate colposcopy, or triage by results of HPV testing. When an ASC-US reading is reported

Figure 11: Management of Women with Atypical Squamous Cells of Undetermined Significance (ASC-US)

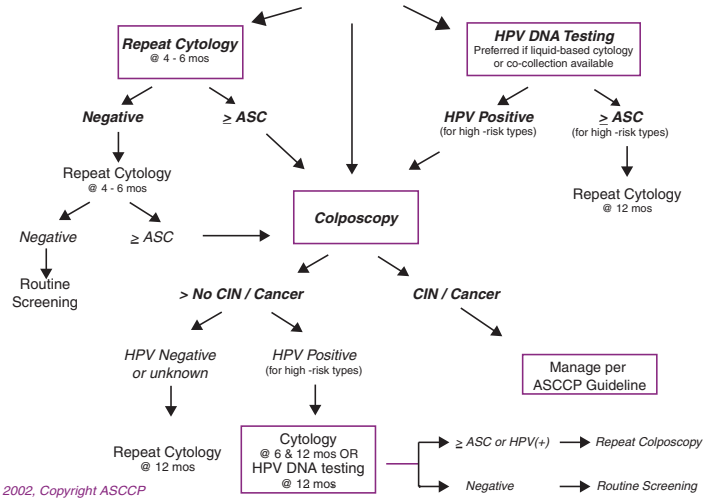

Figure 12: Management of Women with Atypical Squamous Cells of Undetermined Significance (ASC-US) in Special Circumstances

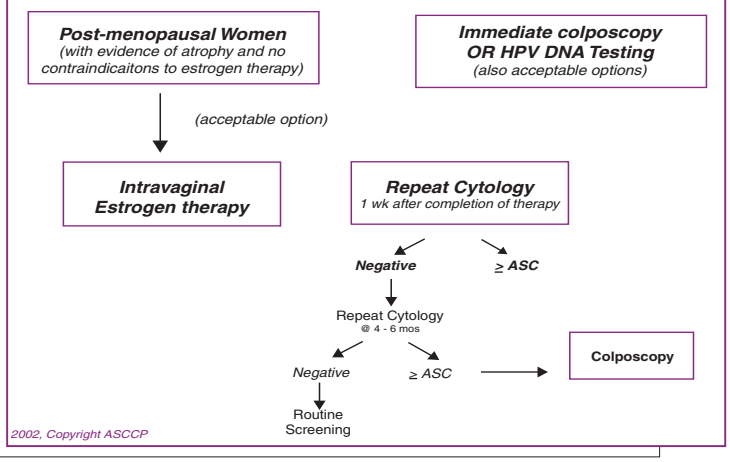

Figure 13: Management of Women with Atypical Squamous Cells: Cannot Exclude High-grade SIL (ASC-H)

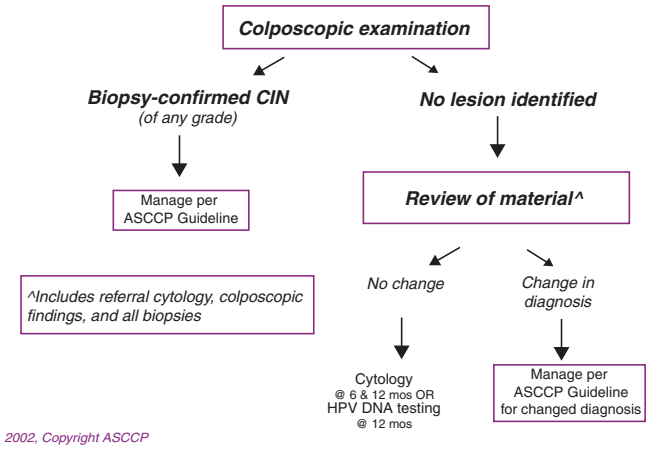

from a liquid-based Pap test, use of the residual sample from the Pap test for HPV DNA testing is preferred, because it prevents a repeat office visit.[2] (See Figures 11 and 12.)

There are three options for performing HPV testing in the context of an ASC-US cytology: having the woman return for HPV testing, using the residual sample from a liquid-based Pap test, or collecting a separate HPV sample at the time of the initial Pap test. The second and third approaches are preferred, because they eliminate the need for a return office visit, and thus are more convenient and potentially cost-saving. If a liquid-based Pap test is used, HPV DNA testing can be performed on residual cells in the liquid-based cervical specimen whenever an ASC-US cytologic abnormality is found on the Pap test. If a conventional Pap test is used, a separate HPV test sample can be collected in the standard Digene hc2 collection kit and stored for later HPV testing if the Pap result is A1SC-US. The HPV test sample should be stored at room temperature until the Pap test results are available. Only samples from women whose Pap test is reported as ASC-US should be sent for HPV testing. The other HPV samples (approximately 95 percent of samples in most clinical settings) should be discarded as medical waste.

If accelerated repeat Pap test is chosen to manage ASC-US, cervical cytologic testing should be conducted at four- to six-month intervals until two consecutive tests are found to be negative, at which time the woman can return to a routine frequency for Pap tests. Women found to have a cytologic abnormality of ASC-US or greater on repeat testing should be referred for colposcopy.[2]

Women with ASC-US managed by immediate colposcopy who are not found to have CIN should receive repeat cytologic testing in 12 months. Women with ASC-US managed by HPV testing should be evaluated by colposcopy if HPV results are positive. If HPV results are negative, these women can be followed with repeat cytologic testing in 12 months.[2]

ASC-US in women who are pregnant should be managed with the same protocol as ASC-US in women who are not pregnant. Immunosuppressed women with ASC-US should be referred for colposcopy. Postmenopausal women with ASC-US may be treated with intravaginal estrogen if there is clinical or cytologic evidence of vaginal atrophy, then should undergo repeat cytologic testing one week after completing the three to four week course of treatment. Women with a negative repeat Pap test result should have a repeat Pap test in four to six months. If both repeat Pap tests are negative, the woman may return to a routine frequency of testing. If either of the repeat tests is positive for ASC-US or greater abnormality, the woman should undergo colposcopy. It is also acceptable to manage ASC-US in postmenopausal women with immediate colposcopy or HPV testing.[2]

Women who have cervical cytological testing that is interpreted as ASC-H should undergo colposcopy (see Figure 13).

Atypical Glandular Cells

Bethesda System terminology. Atypical glandular cells (AGC) may be the most difficult diagnostic challenge of any of the abnormal Pap categories under the Bethesda System. AGC indicates that the cellular changes in glandular cells exceed those expected in a benign reactive or reparative process yet are not abnormal enough to be clearly neoplastic (see Figure 14). AGC represents a much greater risk than ASC-US, because between 10 percent and 39 percent of women with this cytologic interpretation have high-grade squamous or glandular lesions on follow-up.[7,8,9]

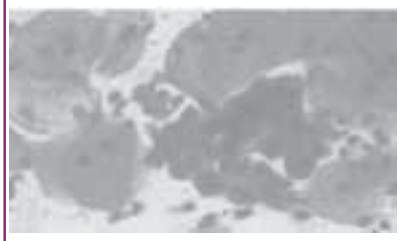

Figure 14: An AGUS Pap smear with glandular cells that do not appear to be completely normal, yet also are not clearly abnormal.

Management. Current management guidelines recommend colposcopy with endocervical sampling for all women with AGC, with the exception of women who have atypical endometrial cells, for whom endometrial sampling is recommended as the initial evaluation (see Figure 15).

Figure 15: Management of Women with Atypical Glandular Cells (AGC)

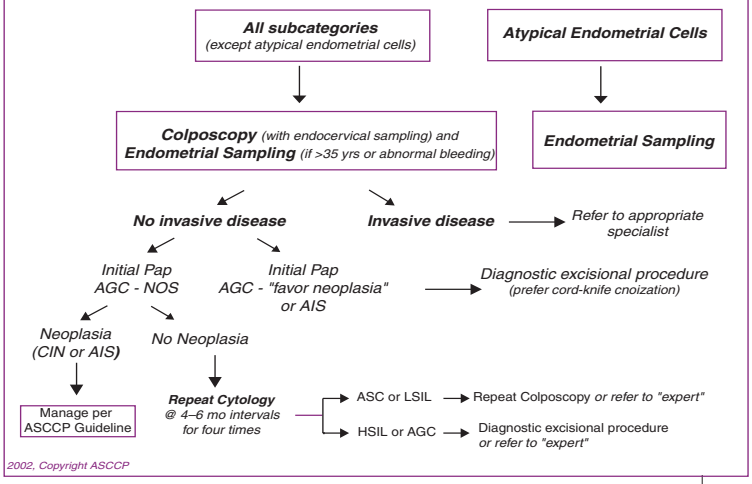

In addition, women with AGC who are over age 35 or who have abnormal unexplained vaginal bleeding should have colposcopy with endometrial sampling.[2] There are currently not sufficient data to assess the utility of HPV DNA testing in women with AGC.

Low-Grade Squamous Intraepithelial Lesions

Bethesda System terminology. Low-Grade Squamous Intraepithelial Lesions (LSIL), especially in young women, often represent a self-limited HPV infection. In some cases, LSIL is associated with an underlying high-grade lesion; approximately 25 percent to 30 percent of women who receive an interpretation of LSIL on cervical cytology will have CIN 2/3 on subsequent biopsy.[7,10,11]

Management. Current management guidelines recommend colposcopy for all women with LSIL.[2] Historically, repeat cytology was frequently used to follow women with LSIL. Repeat cytology was fraught with high rates of loss to follow-up, however, and a high rate of repeat abnormal cytology results—53 percent to 76 percent—requiring referral to colposcopy.[2] Although colposcopy does generate anxiety in patients, referral directly to colposcopy may reduce both psychological morbidity and costs by establishing a diagnosis and lead to more rapid treatment of histologically confirmed significant lesions. HPV testing is not generally useful in women with LSIL because of the high likelihood of high-risk HPV types in this population. HPV testing may be helpful in the management of LSIL in postmenopausal women, however, because HPV-negative cellular changes that mimic LSIL and are not related to cervical neoplasia are common in this age group.[12] Adolescents represent a special circumstance. Because low grade lesions regress and the risk of cancer is so low in this age group, two acceptable options to immediate colposcopy in adolescents are follow-up with 1) repeat cytology at six and 12 months with referral for colposcopy for ASC-US or above, or 2) HPV testing at 12 months with referral for colposcopy if the HPV test is positive. Subsequent management of women referred to colposcopy for LSIL is driven by three factors: whether the colposcopic examination is deemed satisfactory; whether the patient is pregnant, postmenopausal, or an adolescent; and whether a lesion is identified.[2] (See Figures 16, 17, and 18.)

High-Grade Squamous Intraepithelial Lesions

Bethesda System terminology. The separation of squamous intraepithelial lesions into high- and low-grade categories is upheld in the most recent Bethesda System. This reflects the significant data distinguishing the two: LSIL generally represents a transient infection with HPV, and high-grade squamous intraepithelial lesions (HSIL) are more commonly associated with persistence of infection and greater risk of progression.[13,14,15,16] HSIL is an uncommon finding on cervical cytologic testing, occurring in less than 1 percent of Pap results.[17] Women

Figure 16: Management of Women with Low-grade Squamous Intraepithelial Lesions (LSIL)*

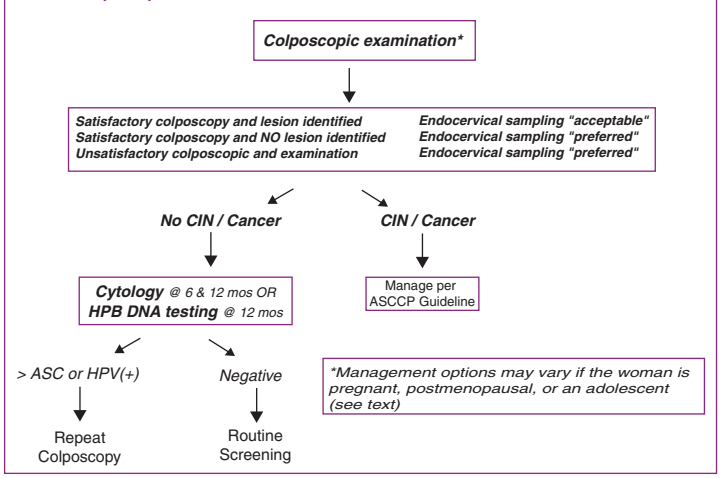

Figure 17: Management of Women with Low-grade Squamous Intraepithelial Lesions in Special Circumstances (Postmenopausal)

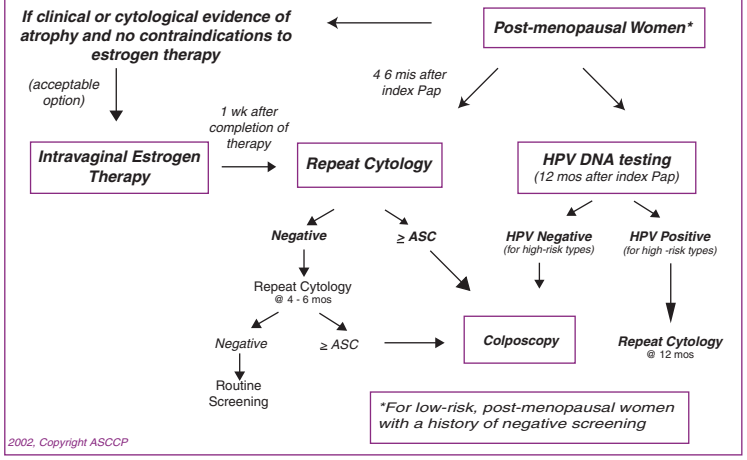

Figure 18: Management of Women with Low-grade Squamous Intraepithelial Lesions in Special Circumstances (Adolescents)

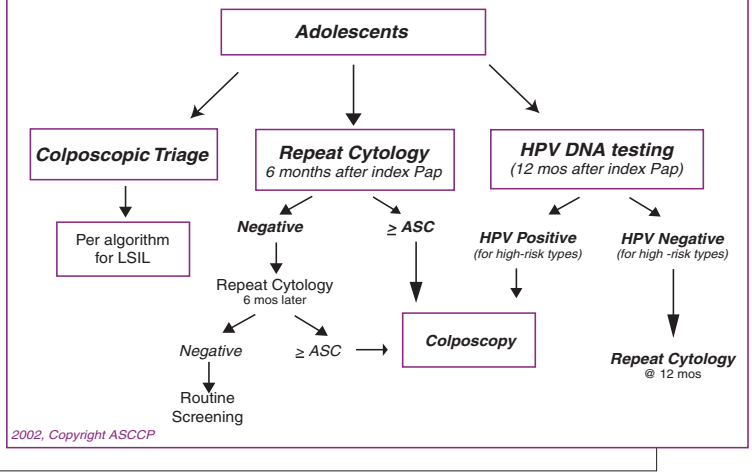

with HSIL do have a high risk of significant abnormalities on subsequent biopsy: a 70 percent to 75 percent chance of CIN 2/3 and a 1 percent to 2 percent chance of cervical carcinoma.[18,19,17] (See Figure 19.)

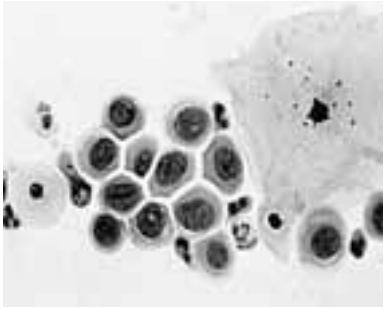

Figure 19: HSIL Pap: Enlarged hyperchromatic nuclei and little cytoplasm

Management. All women with an HSIL interpretation on cervical cytology should undergo colposcopy and, with the exception of pregnant women, endocervical assessment; endocervical sampling is contraindicated in pregnant women.[2] Subsequent management depends on whether the colposcopy is deemed satisfactory, whether a lesion is identified, whether the patient is pregnant, and whether the representative histology has ruled out invasive cancer (see Figure 20). In select settings with transient populations, immediate excision may be considered when patients are at risk for loss to follow-up.

Figure 20: Management of Women with High-grade Squamous Intraepithelial Lesions (HSIL)*

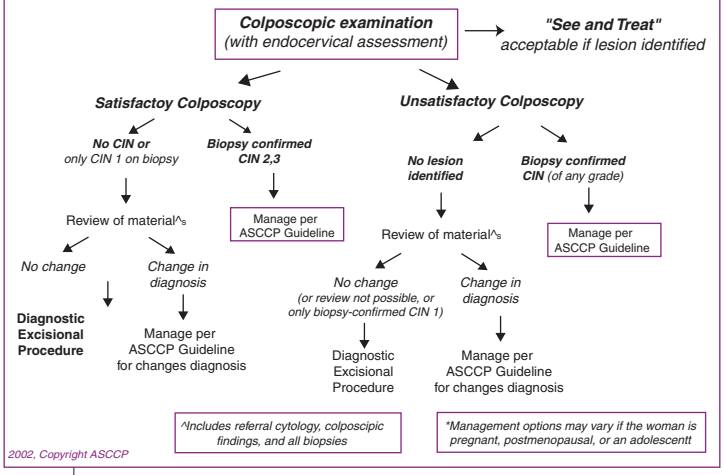

1. Solomon D, Davey D, Kurman R, et al, for the Forum Group Members and the Bethesda 2001 Workshop. The 2001 Bethesda System: terminology for reporting results of cervical cytology. *JAMA.* 2002;287:2114-9.
2. Wright TC, Jr., Cox JT, Massad LS, Twiggs LB, for the 2001 ASCCP-Sponsored Consensus Conference. 2001 consensus guidelines for the management of women with cervical cytological abnormalities. *JAMA.* 2002;287(16):2120-9.
3. Sherman ME, Solomon D, Schiffman M; ASCUS LSIL Triage Study Group. Qualification of ASCUS. A comparison of equivocal LSIL and equivocal HSIL cervical cytology in the ASCUS LSIL Triage Study. *Am J Clin Pathol.* 2001;116(3):386-94.
4. Quddus MR, Sung CJ, Steinhoff MM, et al. Atypical squamous metaplastic cells: reproducibility, outcome, and diagnostic features on ThinPrep Pap test. *Cancer.* 2001;93(1):16-22.
5. Sherman ME, Tabbara SO, Scott DR, et al. "ASCUS, rule out HSIL": cytologic features, histologic correlates, and human papillomavirus detection. *Mod Pathol.* 1999;12(4):335-42.
6. ALTS Group. Results of a randomized trial on the management of cytology interpretations of atypical squamous cells of undetermined significance. *Am J Obstet Gynecol.* 2003a;188:1383-92.
7. Jones BA, Novis DA. Cervical biopsy-cytology correlation. A College of American Pathologists Q-Probes study of 22 439 correlations in 348 laboratories. *Arch Pathol Lab Med.* 1996;120(6):523-31.
8. Soofer SB, Sidawy MK. Atypical glandular cells of undetermined significance: clinically significant lesions and means of patient follow-up. *Cancer.* 2000;90(4):207-14.
9. Eddy GL, Strumpf KB, Wojtowycz MA, et al. Biopsy findings in five hundred thirty-one patients with atypical glandular cells of uncertain significance as defined by the Bethesda system. *Am J Obstet Gynecol.* 1997;177(5):1188-95.
10. Lonky NM, Sadeghi M, Tsadik GW, Petitti D. The clinical significance of the poor correlation of cervical dysplasia and cervical malignancy with referral cytologic results. *Am J Obstet Gynecol.* 1999;181(3):560-6.
11. ALTS Group. A randomized trial on the management of low grade squamous intraepithelial lesion cytology interpretations. *Am J Obstet Gynecol.* 2003b;188:1393-1400.
12. Koutsky LA for the ALTS Group. HPV triage as a management strategy for women with low-grade squamous intraepithelial lesions. *J Nat Cancer Inst.* 2000;92:397-402.
13. Sherman ME, Schiffman MH, Lorincz AT, et al. Toward objective quality assurance in cervical cytopathology. Correlation of cytopathologic diagnoses with detection of high-risk human papillomavirus types. *Am J Clin Pathol.* 1994;102(2):182-7.
14. Stoler MH, Schiffman M. Atypical Squamous Cells of Undetermined Significance-Low-grade Squamous Intraepithelial Lesion Triage Study (ALTS) Group. Interobserver reproducibility of cervical cytologic and histologic interpretations: realistic estimates from the ASCUS-LSIL Triage Study. *JAMA.* 2001;285(11):1500-5.
15. Solomon D, Schiffman M, Tarone R, for the ALTS Group. Comparison of three management strategies for patients with atypical squamous cells of undetermined significance: baseline results from a randomized trial. *J Natl Cancer Inst.* 2001;93:293-9.
16. Slawson DC, Bennett JH, Simon LJ, Herman JM. Should all women with cervical atypia be referred for colposcopy: a HARNET study. Harrisburg Area Research Network. *J Fam Pract.* 1994;38(4):387-92.
17. Jones BA, Davey DD. Quality management in gynecologic cytology using interlaboratory comparison. *Arch Pathol Lab Med.* 2000;124(5):672-81.
18. Kinney WK, Manos MM, Hurley LB, Ransley JE. Where's the high-grade cervical neoplasia? The importance of minimally abnormal Papanicolaou diagnoses. *Obstet Gynecol.* 1998;91(6):973-6.
19. Massad LS, Collins YC, Meyer PM. Biopsy correlates of abnormal cervical cytology classified using the Bethesda system. *Gynecol Oncol.* 2001;82(3):516-22.

Counseling Patients with HPV

Although HPV has been present since the time of the Greeks and the Romans, the recent association of this virus with the development of precancerous lesions and cancer has brought new issues and heightened anxiety to the event of having an abnormal Pap result. Most women are still unfamiliar with HPV and are understandably uncertain of the ramifications of the diagnosis. Ideally, providers should teach their patients about HPV at the beginning of the cervical screening experience. Learning that one has a sexually transmitted disease/infection (STD/STI) is usually very frightening, and women who receive a diagnosis of genital warts or an abnormal Pap result may be quite anxious. Anger, confusion, and blame are often part of the emotional response to receiving news of the presence of any STD/STI, and HPV is no exception. Added to this are the uncertainty about cause, controversies about treatment, fear of cancer, and anxiety about the possibility that treatment of the cervix may lead to a major life consequence such as infertility.

Clinicians who care for women receiving this diagnosis must be prepared to answer questions factually and to clarify the questions that do not yet have answers. This is especially true given the availability of testing for HPV. Clinicians who order HPV testing must understand the key issues and implications of HPV testing and be able to responsibly communicate these topics to women. Clinicians and patients should also be aware that the availability of HPV testing and the potential for reducing the frequency of cervical screening for women with normal results do not negate the need for routine preventive health maintenance visits that include pelvic bimanual examinations and breast cancer screening—interventions that have historically been performed at the time of "the annual Pap."

It is very important for patients to understand that the majority of sexually active individuals will be infected with HPV at some point in their lifetime and that the infection is generally transient and cleared by the immune system. They should understand that most young women with mild cellular changes have been infected with high-risk HPV types. They should also understand that most infections are cleared to undetectable viral levels, so a diagnosis of HPV only rarely leads to the development of a significant lesion. Only women with persistent infection with a high-risk HPV type are at risk. Women should know that cervical cancer is rare, and that it can be prevented or successfully treated with proper follow-up and early intervention.

It is also helpful to empower patients by exploring behavior changes that have the potential to reduce their risk of developing cervical cancer, such as smoking cessation. Practicing safer sex can reduce their risk for sexually transmitted infections, including HPV and HIV. However, condoms are not entirely effective in preventing HPV infections. (For information about safer sex practices, please refer to http://www.plannedparenthood.org/sti/.)

A woman's usual system of support on which she has depended for other crises in her life may or may not seem appropriate when addressing the diagnosis of HPV. Culturally sensitive, educationally appropriate written information can reinforce your counseling and give the patient another opportunity to process helpful information in the privacy of her own home. Patients do not absorb all of the information that is discussed when they first receive the diagnosis. Give them an opportunity to return and discuss the information at a later date. Support groups can be helpful. Remember that some patients who are dealing with other stressful events in their lives may need to be referred for more psychological counseling if concerns do not diminish. A resource list is provided at the end of this section to help you find appropriate educational materials.

Examination of the sexual partner of a woman who develops genital warts or CIN is not considered necessary, because there is no evidence that re-infection with the same viral type plays a role in recurrence, but a new sexual partner is at risk for infection.

The following questions and responses regarding issues related to HPV and cervical screening were prepared in 2003 by Drs. Thomas Cox and Debbie Saslow with input from many other individuals with expertise in cervical screening and HPV. This information is posted and updated regularly at the American Cancer Society's Web site, http://www.cancer.org. We hope that these will be helpful for counseling patients with HPV.

What is cervical cancer? How common is it?
Cervical cancer is cancer that begins in the cervix, the part of the uterus or womb that opens to the vagina. Cervical cancer was once the number one or two cause of death from cancer in women. Thanks to the Pap test, the number of women in the United States who get cervical cancer has decreased. Now a new test is available that might improve on the Pap test and help women to prevent cervical cancer. Cervical cancer can be prevented in most cases by early detection.

What is HPV? How does it lead to cervical cancer?
HPV is short for human papillomavirus. An HPV infection is usually harmless and temporary: most people with HPV will never know they are infected because the virus usually goes away on its own. There are many types of this common virus, and only a few "high-risk" types can lead to cervical cancer. These high-risk HPV types are spread through sexual contact. There are also "low-risk" types of HPV that can cause genital warts but do not cause cancer. If high-risk HPV types don't go away on their own, they may progress to pre-cancer cells. If these abnormal cells are not found and treated, they may become cancer with time. However, most cell changes return to normal by themselves. It is very rare for an HPV infection to lead to cervical cancer.

Who can get cervical cancer?
Because almost all cervical cancers are caused by HPV, any woman who has had sex can get (is at risk for) cervical cancer. Some things place women at more risk than others. These include high-risk types of HPV infection, smoking, and HIV infection. The women who are most at risk are those women who are not getting Pap tests at all, or who don't get them for several years.

Who can get HPV?
Anyone who has ever had sex, both men and women, can get an HPV infection. It is estimated that three out of every four people will get an HPV infection during their lifetime. HPV infection is spread by direct skin-to-skin contact during vaginal sex. HPV infection is more common in younger age groups, particularly in women in their late teens and 20s. Because HPV is spread mainly through sex, your chances of getting it increase with number of sex partners. Women who start having sex at a young age, who have many sex partners, and whose sex partners have or have had many other partners are at increased risk for having an HPV infection.

Will I know if I have HPV?
In most cases, infection with the HPV virus has no symptoms. However, a high-risk HPV infection may cause changes in the cervical cells. These changes will show up on your Pap test. Signs of HPV infection can appear weeks, months, or years after first infection, so it is possible to become infected without being aware of it. Only a small number of women infected with HPV develop cell changes.

Can HPV infections be treated?
There is no treatment available for the virus itself. However, there are treatments for cervical changes that HPV can cause. Your health care provider will discuss these treatment options with you, if you need them.

Is there a test for HPV?
Yes, there is an HPV test that can detect high-risk types of HPV in cervical cells. HPV tests are already used to help doctors decide which women with certain abnormal results (called "ASC-US") on their Pap test need further testing. Now this test can also be used in routine testing of women over the age of 30 at the same time that they get their Pap test.

What is a Pap test? What is the difference between a Pap test and an HPV test?
A Pap test is the standard way to see if there are any cell changes that you should be concerned with. The Pap test looks at a sample of cells from the cervix under a microscope to see if there are any cells that are abnormal. It is a very good test for finding not only cervical cancer cells but also cells that might become cancer cells. Usually health care providers do the Pap test as part of a pelvic exam.

An HPV test checks directly for high-risk HPV viruses. For both the Pap test and HPV test, a small soft brush is used to collect cervical cells that are sent to a laboratory. Whether you get both tests or the Pap test alone, you will not notice a difference in your exam.

Should I be tested for HPV infection?
If you are more than 30 years old, you can get both an HPV test and a Pap test at the same time. Getting both tests together makes it more likely that any abnormal cervical cell changes will be found compared with using just one test. If both test results are negative (normal), you should not repeat either test more often than every three years. The choice of whether or not to be tested for HPV is yours, and you should discuss your decision and possible results with your health care provider. You also may want to ask about the cost of the test and whether your insurance will cover that. Remember, it will still be important to continue having routine health exams.

You can also choose to get a regular Pap test without an HPV test, or the new liquid-based Pap test. For finding cervical cancer or cell changes early, it is much more important to get tested at all than to get a particular kind of test.

I am under age 30—should I get an HPV test in addit ion to my Pap test?
HPV is very common in women under the age of 30, and cervical cancer is very rare in this age group. In most women younger than 30 who have HPV, the virus will go away before it causes any cell changes or symptoms. Including an HPV test along with your Pap test provides no real health benefit for younger women and might lead to too many tests and unnecessary treatment.

normal. About half of the women with ASC-US have these cell changes because of the presence of HPV. Your doctor suggested you get the HPV test to see if your abnormal cells changes were caused by HPV. Only women with ASC-US who test positive for HPV need further tests. HPV testing is helpful at any age for deciding which women with ASC-US need follow-up. This is different from using an HPV test with the Pap test as part of a normal health visit for women over age 30.

How should I prepare for a Pap test or Pap and HPV test?
Try not to schedule an appointment for a time during your menstrual period. For 48 hours before the test: do not douche; do not have sexual intercourse; do not use tampons, birth control foams, jellies, or other vaginal creams or vaginal medications.

If I tested positive for HPV, what does this mean for me?
Women with a normal Pap result who test positive for HPV will usually be tested for HPV again in six to 12 months. Testing positive a second time does not mean that there is great risk of cervical cancer, or even that cell changes may lead to cervical cancer, but it does mean that further tests will likely be recommended. If you have a positive HPV test result and an abnormal Pap result, your health care provider will explain what further tests you might need.

If I test positive for HPV, when did I get it?
It is usually impossible to know when a person got HPV or from whom. HPV may be found fairly soon after contact, or not until many years later. Most men and women are not aware that they have the virus. Condoms do not offer complete protection from HPV. The virus is so common that having only one lifetime partner does not assure protection. For all these reasons, it is not helpful, or fair, to blame your partner.

If I have an HPV infection that goes away, can I get it again?
Most sexually active couples share the HPV until the immune response eliminates the infection. Partners who are sexually intimate only with each other do not pass the virus back and forth. In other words, when the virus is shared, being exposed to more of the same virus by your partner does not make it more difficult to get rid of the infection. When HPV infection goes away, the immune system will remember that HPV type and keep a new infection of the same HPV type from ever occurring again. However, because there are many different types of HPV, becoming immune to one HPV type does not protect you from getting another HPV type.

If I have HPV or a cell abnormality, is there anything I can do?
Yes: don't smoke. Smoking has been shown to increase the chance that cell abnormalities might progress to more severe changes. Remember that almost everyone gets HPV at some time. Be sure to keep your follow-up doctor appointments.

Will I always have the HPV virus?
No one really knows, but probably not. HPV usually goes away within one to two years.

Key Points to Remember

- Almost all women will have HPV at some point, but very few will develop cervical cancer.
- Most HPV infections are temporary and go away on their own.
- Only HPV infection that does not go away over many years can lead to cervical cancer. Cervical cancer is preventable. Early detection of abnormal cell changes is important.
- Cervical cancer is rare and almost always prevented through regular Pap tests that look for cervical cell changes that could lead to cancer.
- It can be helpful to know your HPV status if you are over age 30. This can help determine how often your health care provider will recommend that you get Pap tests.
- Don't blame yourself or others. Your HPV status is not a reliable indicator of your sexual behavior or that of your partner.

The following resources may also be helpful for counseling patients with HPV:

- ARHP Quick Reference Guide to Patient Questions About HPV
  http://www.arhp.org/guide
- What Women Should Know about HPV and Cervical Health
  http://www.asccp.org/patient_edu.shtml
- HPV Testing—Is It for Me?
  http://www.asccp.org/patient_edu.shtml
- Early Detection of Cervical Cancer
  http://www.cancer.org
- Human Papillomavirus
  http://www.ashastd.org
- Safer Sex Practices
  http://www.plannedparenthood.org/sti/

New Developments in Cervical Cancer Screening and Treatment

The development of liquid-based Pap test technology and easily accessible HPV testing, along with new guidelines incorporating HPV testing with the use of cervical cytology, represent significant improvements in cervical cancer screening and management. Other important advances in prevention, screening, and treatment of CIN and cervical cancer are under development.

HPV vaccines are being evaluated for the prevention of HPV infection and subsequent cervical cancer. A 2002 study found that immunization of 2,392 women 16 to 23 years of age with an HPV type 16 vaccine prevented development of persistent HPV 16 infection in all who received the vaccine, compared with a 3.8 per 100 woman-years risk in those who received the placebo ($p<0.001$.)[1] All nine cases of HPV 16-related CIN occurred in women who received the placebo. The median follow-up period for this study was only 17.4 months; therefore, long-term efficacy of the vaccine has not yet been proven.

New modes of screening for cervical cancer are also in development. A paper-based HPV DNA screening test is being studied in India. Coupled with a single-step DNA extraction procedure, the test allows for dry collection of cervical cells, along with transportation and storage at room temperature.[2] There are also new HPV tests under development. A new automated screening test for HPV, called the Automated Cellular Imaging System (ACIS®), is being evaluated. Two prototype PCR tests for HPV are being developed for use in conjunction with liquid cytology media, such as Thin-Prep®. These tests may allow for improved ability to distinguish high-risk from low-risk HPV.

The potential for treatment of HPV infections with vaccination is also being investigated. Researchers have found that immunization with HPV early proteins has therapeutic and preventive efficacy in animals, but human trials have not yet been successful. Vaccination, probably combined with immunomodulators for maximal response, may be an effective intervention for low-grade epithelial lesions.[3]

---

1. Koutsky LA, Ault KA, Wheeler CM, et al. A controlled trial of a human papillomavirus type 16 vaccine. *N Engl J Med.* 2002;347:1645-51.
2. Sharma D. Paper smear method for rapid HPV testing. *Lancet Oncol.* 2002;3(8);454.
3. Stanley MA. Prognostic factors and new therapeutic approaches to cervical cancer. *Virus Res.* 2002;89(2):241-8.

Conclusions

The introduction of the Pap smear in 1943 revolutionized the prevention of cervical cancer, reducing by more than 70 percent the mortality from this disease. More recently, liquid-based cervical cytologic methods have been developed, and recognition of the causative link between HPV infection and cervical cancer has altered prevention strategies. The development and widespread availability of HPV DNA testing have allowed for an assessment of risk and an objective measure on which to plan the frequency of follow-up testing. These changes have prompted new recommendations for the screening and management of cervical lesions. Clinicians need to be aware of these recent changes and their implications for clinical practice and be able to clearly explain HPV infection and its management to patients.

Clinical Advisory Committee

Nancy Berman, MSN, APRN, BC
Nurse Practitioner
Northwest Internal Medicine Associates
Division of Millennium Medical Group, PC
Southfield, MI

J. Thomas Cox, MD
Director
Women's Clinic
University of California, Santa Barbara
Santa Barbara, CA

Diane Solomon, MD
Breast and Gynecologic Cancer Research Group
Division of Cancer Prevention, NCI, NIH, DHHS
Bethesda, MD

Financial Disclosure Information

The following committee members have a financial interest or affiliation with the manufacturers of commercial products possibly related to topics covered in this issue of *Clinical Proceedings*®. These financial interests or affiliations are in the form of grants, research support, speaker support, and/or other support. This support is noted to fully inform readers and should not have an adverse impact on the information provided within this publication.

Berman: Speaker for 3M, Digene.

Cox: Consultant for 3M, Digene; speaker for 3M, Cytyc, Digene.

Solomon: Project director for the National Cancer Institute-funded ALTS trial, which received support in the form of equipment and/or supplies at reduced cost or no cost from the following vendors: Digene, Cytyc, DenVu, NTL, and TriPath.

ARHP Board of Directors

Executive Committee
Felicia H. Stewart, MD, *Chair*
Lee Lee Doyle, PhD, *Chair-Elect*
Cookie Bible, NP, *Secretary*
Lee Shulman, MD, *Treasurer*
Mitchell Creinin, MD, *Chair, Education Committee*
Wayne C. Shields, *President and CEO*

Directors-at-Large
Barbara Clark, PA-C
Charlotte Ellertson, PhD
Henry Foster, Jr., MD
Pablo Rodriguez, MD
Sharon Schnare, RN, FNP, CNM, MSN
Carolyn Westhoff, MD
Sandy Worthington, RNC, NP

Standing Positions
Vanessa Cullins, MD, MPH, MBA
PPFA Vice President for Medical Affairs
Leslie Walton, MD
PPFA National Medical Committee Representative

Contributing ARHP Staff

Elizabeth S. Callihan, *Consulting Designer*
Diane Shannon, MD, MPH, *Consulting Writer*
Cynthia M. Lopez, *ARHP Program Associate*
Barbara Shapiro, *Consulting Editor*
Wayne C. Shields, *ARHP President and CEO*
Amy M. Swann, *ARHP Director of Education*

Association of Reproductive Health Professionals

2401 Pennsylvania Avenue, NW, Suite 350 ◆ Washington, DC 20037-1718 USA
Phone: (202) 466-3825 ◆ Fax: (202) 466-3826
E-Mail: arhp@arhp.org ◆ Web: www.arhp.org

© 2003 Association of Reproductive Health Professionals

Advances in Cervical Cancer Prevention

Post-Test

Please circle the best answer for each question.

1. Which of the following HPV type is associated with the highest risk of cervical cancer?
   a. 16
   b. 10
   c. 6
   d. 11

2. The most common mode of HPV transmission is:
   a. Vertical
   b. Via fomites
   c. Sexual
   d. None of the above

3. Which region of the HPV genome is crucial in the process of oncogenesis?
   a. Retinoblastoma gene
   b. E6 region
   c. p53 gene
   d. None of the above

4. The cervical transformation zone:
   a. Is an area especially protected from oncogenic transformation
   b. Marks the junction between the squamous and glandular cells of the cervix
   c. Is a common site for genital warts but not cervical carcinoma
   d. None of the above

5. The liquid hybridization HPV DNA test:
   a. Is more specific than liquid-based Pap smear for women with identifying CIN 3 or higher
   b. Is more sensitive than liquid-based Pap smear for women with identifying CIN 3 or higher
   c. Identifies HPV type 18 only
   d. Is not yet widely available

6. Current ACS guidelines for primary screening of cervical cancer include all of the following recommendations EXCEPT:
   a. Screening should begin three years after a woman begins having vaginal intercourse, but not later than age 21
   b. Screening with conventional or liquid-based Pap smear technology should be conducted annually
   c. Women with HIV should be screened more frequently than routine
   d. Once a women 30 years of age or older has three consecutive normal results, she can reduce frequency of testing to once every two to three years

7. The three general reporting elements of the 2001 Bethesda System include all of the following EXCEPT:
   a. Interpretation/result
   b. Risk stratification
   c. General categorization
   d. Specimen adequacy

8. Which is FALSE about the management of ASC?
   a. Women with ASC-H should only undergo colposcopy
   b. Women with ASC-US should only undergo colposcopy
   c. Women who are pregnant and found to have ASC-US should be treated with the same protocol as women who are not pregnant
   d. None of the above is false

9. Key points to make when counseling women with HPV include:
   a. Cervical cancer is rare
   b. The majority of sexually active individuals will be infected with HPV at some point in their lifetime
   c. Certain types of HPV are responsible for cervical cancer, but not all types are associated with the disease
   d. All of the above

10. Which is NOT true about HPV vaccine?
    a. The HPV vaccine is being studied as a means of preventing HPV infection and subsequent cervical cancer
    b. The HPV vaccine is being studied as an effective intervention for low-grade epithelial lesions
    c. The HPV vaccine was found in one study to prevent persistent HPV infection in all who received the vaccine
    d. The HPV vaccine has been evaluated in long-term studies

Program Evaluation

On a scale of 1 to 5, with 5 being the best, please rate this *Clinical Proceedings*® in terms of the following:

1. Extent to which stated program objectives are met.
   a. Describe the most common genital HPV types in benign and malignant disease.
      5 4 3 2 1
   b. Identify the most common modes of HPV transmission.
      5 4 3 2 1
   c. Describe the natural history of HPV.
      5 4 3 2 1
   d. Understand the natural history of cervical intraepithelial neoplasia.
      5 4 3 2 1
   e. Understand new technological developments in cervical cancer screening and treatment.
      5 4 3 2 1
   f. Discuss the current recommendations for primary screening of cervical cancer.
      5 4 3 2 1
   g. Describe two recent developments in cervical cancer screening.
      5 4 3 2 1
   h. List the three elements of The Bethesda System (TBS) in Pap test reporting.
      5 4 3 2 1
   i Describe management options for cervical epithelial abnormalities.
      5 4 3 2 1
   j .Understand the psychosocial and counseling issues related to HPV and cervical cancer.
      5 4 3 2 1
2. Relevance to clinical practice
   5 4 3 2 1
3. Increased understanding of the topic
   5 4 3 2 1
4. Extent to which stated program objectives are met
   5 4 3 2 1
5. Effectiveness of teaching/learning methods
   5 4 3 2 1
6. Usefullness of materials such as this that are supported by educational grants from industry
   5 4 3 2 1
7. Please comment on the scientific rigor, fairness, and balance of the material: _____
   _____
   _____
8. What topics would you suggest for future programs?
   _____
   _____

Credit Request Form

Participants who correctly answer 70% or more of the questions on the post-test will receive continuing education credit. To obtain credit, return a copy of both sides of this form with a processing fee of $15 by March 31, 2005 to:

ARHP
2401 Pennsylvania Avenue, NW, Suite 350
Washington, DC 20037-1718 USA

Name: _____

Degree: _____

Affiliation: _____

_____

Street Address: _____

_____

City, State, Zip: _____

E-mail: _____

Signature: _____

Please indicate the total time you spent on this educational activity: ___ hours ___ minutes

Please indicate your payment method:

❒ Check enclosed, payable to ARHP.

❒ Charge my AMEX/VISA/MasterCard:

Card Number: _____

Expiration Date: _____